



IUSS

Scuola Universitaria Superiore Pavia



FONDAZIONE
MONDINO

Istituto Neurologico Nazionale
a Carattere Scientifico | IRCCS

PRIMARY PROGRESSIVE APHASIAS

Stefano F. Cappa

University Institute of Advanced Studies
and Mondino Foundation

Pavia, Italy

stefano.cappa@iusspavia.it

Disclosure

- None

Learning objectives

- The learner will be able to:
 - Diagnose primary progressive aphasia (PPA) on the basis of a clinical examination
 - Request the appropriate tests to support the diagnosis
 - Diagnose the subtype of PPA and the most likely pathological cause
 - Propose a management plan to patient and family

Key message

- PPAs are a group of phenotypic presentations of different neurodegenerative disorders
- PPA is not rare in cognitive/behavioural neurology practice
- A correct diagnosis has prognostic and management relevance



Classification of primary progressive aphasia and its variants

M.L. Gorno-Tempini, MD, PhD
 A.E. Hillix, MD
 S. Weintraub, PhD
 A. Kertesz, MD
 M. Mendez, MD
 S.F. Capps, MD
 J.M. Ogar, MS
 J.D. Rohrer, MD
 S. Black, MD
 B.F. Boeve, MD
 F. Manes, MD
 N.F. Dronkers, PhD
 R. Vandenberghe, MD, PhD
 K. Racovsky, PhD
 K. Patterson, PhD
 B.L. Miller, MD
 D.S. Knopman
 J.R. Hodges, MD*
 M.M. Grossman, MD*
 M. Grossman, MD*

Address correspondence and reprint requests to Dr. Maria Luisa Gorno-Tempini, Memory and Aging Center, Department of Neurology (C222), 705 University Avenue, Suite 901, San Francisco, CA 94143-2207.
 mlt@gornotempini.ucsf.edu

Editorial, page 042

ABSTRACT
 This article provides a classification of primary progressive aphasia (PPA) and its 3 main variants to improve the uniformity of case reporting and the reliability of research results. Criteria for the 3 variants of PPA—nonfluent/agrammatic, semantic, and logopenic—were developed by an international group of PPA investigators who convened on 3 occasions to operationalize earlier published clinical descriptions for PPA study sites. Patients are first diagnosed with PPA, and are then divided into clinical variants based on specific speech and language features characteristic of each subtype. Classification can then be further specified as “imaging-supported” if the expected pattern of atrophy is found and “with definite pathology” if pathologic or genetic data are available. The working recommendations are presented in lists of features, and suggested assessment tasks are also provided. These recommendations have been widely agreed upon by a large group of experts and should be used to ensure consistency of PPA classification in future studies. Future collaborations will collect prospective data to identify relationships between each of these syndromes and specific biomarkers for a more detailed understanding of clinicopathologic correlations. *Neurology*® 2011;76:1006-1014

GLOSSARY
 AD = Alzheimer disease, FTLD = frontotemporal lobar degeneration, PPA = primary progressive aphasia

A progressive disorder of language associated with atrophy of the frontal and temporal regions of the left hemisphere was first described in the 1890s by Pick¹ and Serieux.² In the modern literature, Mesulam³ described a series of cases with “slowly progressive aphasia,” subsequently renamed primary progressive aphasia (PPA).⁴ Warrington⁵ described a progressive disorder of semantic memory in 1975. This condition was also described by Snowden et al.⁶ as semantic dementia. In the early 1990s, Hodges and colleagues⁷ provided a comprehensive characterization of semantic dementia. Subsequently, Grossman et al.⁸ described a different form of progressive language disorder, termed progressive nonfluent aphasia. A consensus meeting attempted to develop criteria for these conditions in relation to frontotemporal lobar degeneration.⁹ For about 2 decades, cases of PPA were generally categorized as semantic dementia or progressive nonfluent aphasia, or in some studies as “fluent” vs “nonfluent.” However, there

In-Press ahead of print on February 18, 2011 at www.neurology.org
 *These authors contributed equally to this work.
 From the Memory and Aging Center (M.L.G.-T., J.M.O., K.R., B.L.M.), Department of Neurology, University of California at San Francisco, San Francisco; Center for Molecular Studies (M.L.G.-T.), University of Turin, Turin, Italy; Department of Neurology (A.E.H.), Johns Hopkins University, Baltimore, MD; Department of Neurology (S.W., M.M.G.), Northwestern University, Chicago, IL; Cognitive Neurology (A.E.H.), University of Western Ontario, London, Canada; Department of Neurology (M.M.), University of California at Los Angeles, Los Angeles; University of Washington (J.M.O.), Seattle; Johns Hopkins University (K.R.), Baltimore; Department of Neurology, University College London, London, UK; Department of Medicine (Neurology) (S.F.), Sunnybrook Health Sciences Centre, University of Toronto, Toronto, Canada; Department of Neurology (J.D.R., D.S.K.), Mayo Clinic, Rochester, MN; Institute of Cognitive Neurology (F.M.), Buenos Aires, Argentina; VA Northern California Health Care System and University of California, Davis (N.F.D.); Department of Neurology (B.V.), University of Leuven, Leuven, Belgium; Department of Clinical Neurosciences (B.F.), University of Cambridge, Cambridge, UK; Neuroscience Research Australia and University of New South Wales (R.V.), Australia; and Department of Neurology (M.C.), University of Pennsylvania, Philadelphia.
 Study Funding: National Institute of Neurological Disorders and Stroke (R01NS050515), National Institute on Aging (P01AG022010) and P01 AG029724 (M.L.G.-T.); National Institute on Deafness and Communication Disorders (DC008102), National Institute on Aging (Alzheimer Disease Cause and Effect), NINDS (DC008102) (M.M., S.W.), AGING (AG011434), NINDS (NS058363), The Wellcome Trust and a Sloan Trust Scholarship (J.R.); HD042949-01 (J.M.O.); NIH HD054071 and HD052457 (A.E.H.); National Institute on Aging, P01 AG014574, HD042949, HD042948, and U24 AG020795, and the Alzheimer's Association (2852-09-14140) (B.F.); and research from the Australian Research Council (D.S.K.).
 Disclosure: Author disclosures are provided at the end of this article.
 Received June 9, 2010; revised Oct 14, 2010; accepted Oct 14, 2010. Copyright © 2011 by AAN Enterprises, Inc. Unauthorized reproduction of this article is prohibited.



When to suspect a PPA?


(Mesulam 2003 criteria, modified)

- Inclusion
 - Most prominent clinical feature is a language impairment (aphasia)
 - This impairment is the only determinant of difficulties in the activities of daily living
 - Aphasia is the most prominent disorder at onset and in the early phase of disease
- Exclusion
 - Aphasia can be due to non neurodegenerative or other medical causes
 - Aphasia can be attributed to a psychiatric disorder
 - Prominent early episodic memory or visuo-spatial disorders
 - Prominent early behavioural disturbances

How to diagnose a PPA?

- Quantitative/qualitative analysis of connected speech
- Naming and comprehension of single words
- Repetition
- Comprehension of grammatically complex sentences

The analysis of connected speech



What to look for?

- Motor speech production
- Other disorders of fluency (pauses and repetitions)
- Lexical/semantic errors
- Grammar (morphology, syntax)

How to diagnose a PPA?

- Quantitative/qualitative analysis of extended production
- Naming and comprehension of single words
- Repetition
- Comprehension of syntactically complex sentences


A comprehensive semantic memory test

- Picture naming
- Naming from verbal description
- Word-picture matching
- Picture sorting
- Feature generation and verification

Naming from verbal description

“It is a fruit, it is yellow, with the shape of a half-moon. Monkeys like them very much»

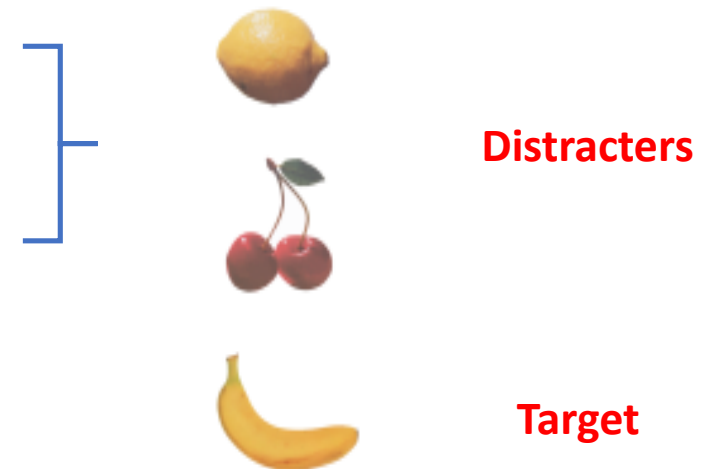
Picture naming



Word-picture matching

Sorting

Feature generation and verification



How to diagnose a PPA?

- Quantitative/qualitative analysis of extended production
- Naming and comprehension of single words
- **Repetition**
- Comprehension of syntactically complex sentences

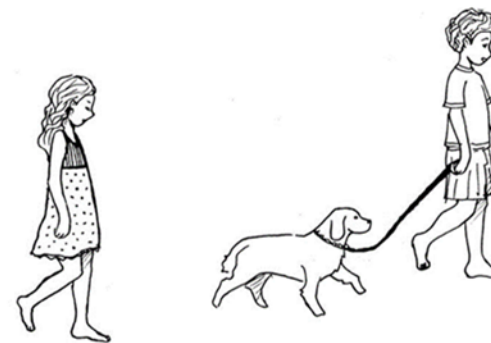
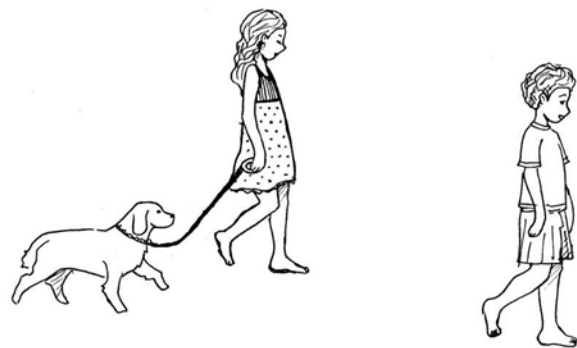
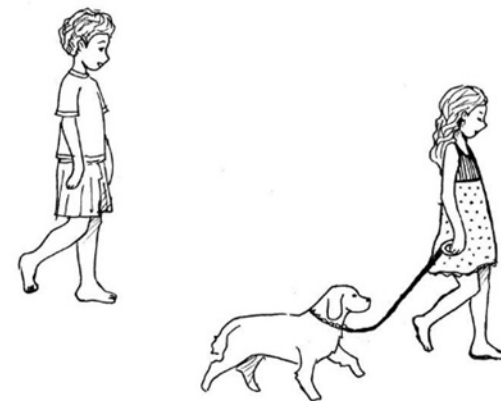
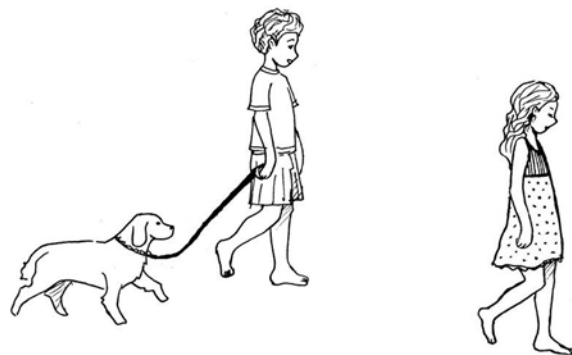
A comprehensive assessment of repetition

- Vowels and syllables
- Digits
- Words
- Pseudowords
- Sentences of increasing length

A “core” assessment procedure

- Quantitative/qualitative analysis of extended production
- Naming and comprehension of single words
- Repetition
- Comprehension of syntactically complex sentences

The boy and the dog are being followed by the girl




The new screening battery for aphasia

Italian version

1. Picture naming (14)
2. Sentence comprehension (8)
3. Single word comprehension (12)
4. Repetition (6 words, 4 nwnds)
5. Repetition of sentence (6)
6. Reading (16)
7. Written description (1)
8. Semantic knowledge (pictures) (4)
9. Connected speech (1)

10-15 min

SAND: a Screening for Aphasia in NeuroDegeneration. Development and normative data

Eleonora Catricalà¹  • Elena Gobbi² • Petronilla Battista^{1,3,4} • Antonio Miozzo⁵ • Cristina Polito⁶ • Veronica Boschi¹ • Valentina Esposito² • Sofia Cuoco⁷ • Paolo Barone⁷ • Sandro Sorbi⁴ • Stefano F. Cappa^{1,8} • Peter Garrard⁹

Test Materials:

User's Manual

Norms Guide

Scoring Template

SAND
Screening for Aphasia in NeuroDegeneration
Protocollo di risposta

Data valutazione: _____
Tempo somministrazione (min): _____
Punteggio MMESE: _____ / 50

Scree	Scree	Scree	Scree	1. Italiano	2. Altri
Nome e Cognome	Nome e Cognome	Nome e Cognome	Nome e Cognome		
Età di nascita	Età di nascita	Età di nascita	Età di nascita		
Età	Età	Età	Età		
Scrittura	Scrittura	Scrittura	Scrittura		
Ascolto le parole	Ascolto le parole	Ascolto le parole	Ascolto le parole		
Ascolto e ascolto	Ascolto e ascolto	Ascolto e ascolto	Ascolto e ascolto		
Professione (Edinburgh Hax)	Professione (Edinburgh Hax)	Professione (Edinburgh Hax)	Professione (Edinburgh Hax)		
Prima lingua	Prima lingua	Prima lingua	Prima lingua		
Intelligenza	Intelligenza	Intelligenza	Intelligenza		
Se ripete solo parole?	Se ripete solo parole?	Se ripete solo parole?	Se ripete solo parole in italiano?		
Deficit motori	Deficit motori	Deficit motori	Deficit motori		
Deficit visivi	Deficit visivi	Deficit visivi	Deficit visivi		
È capace di riferire	È capace di riferire	È capace di riferire	È capace di riferire		
Altri eventuali d	Altri eventuali d	Altri eventuali d	Altri eventuali d		
È stato	È stato	È stato	È stato		
È cambiato	È cambiato	È cambiato	È cambiato		

Clinical variants

- Non fluent/agrammatic
- Semantic
- Logopenic/phonological
- Other variants

Semantic variant

- Fluent speech, with anomias and semantic paraphasias
- **Naming and single word comprehension impairment**
- **Impaired nonverbal semantics**

Case S.P. ♂ 63 years old, 13 years of education, svPPA (GRN +)

Figure 2. Axial T1-weighted MRI images at the diagnosis (A) and at a 18-month follow up (B)

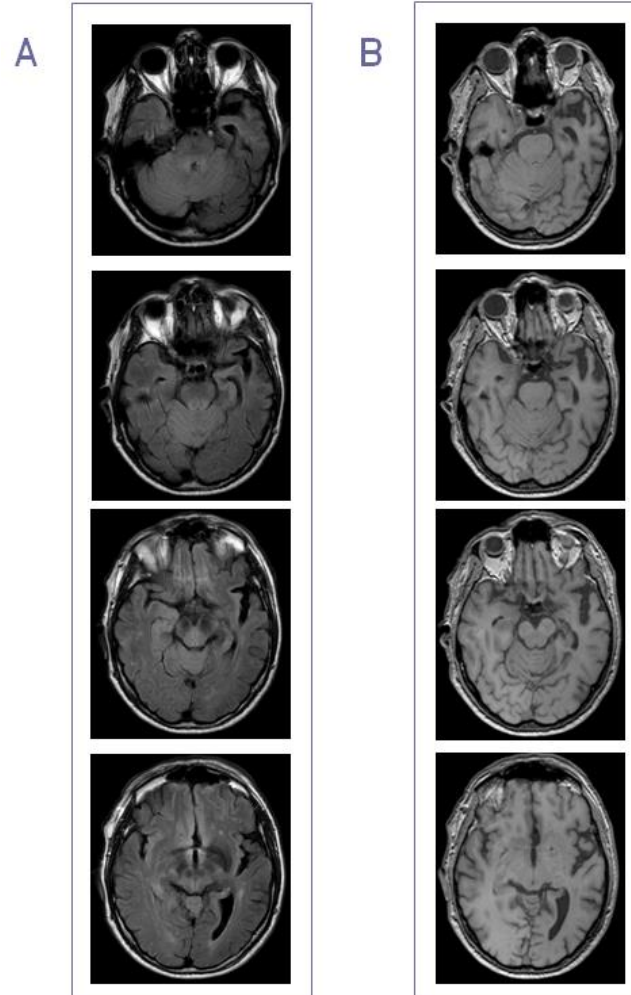
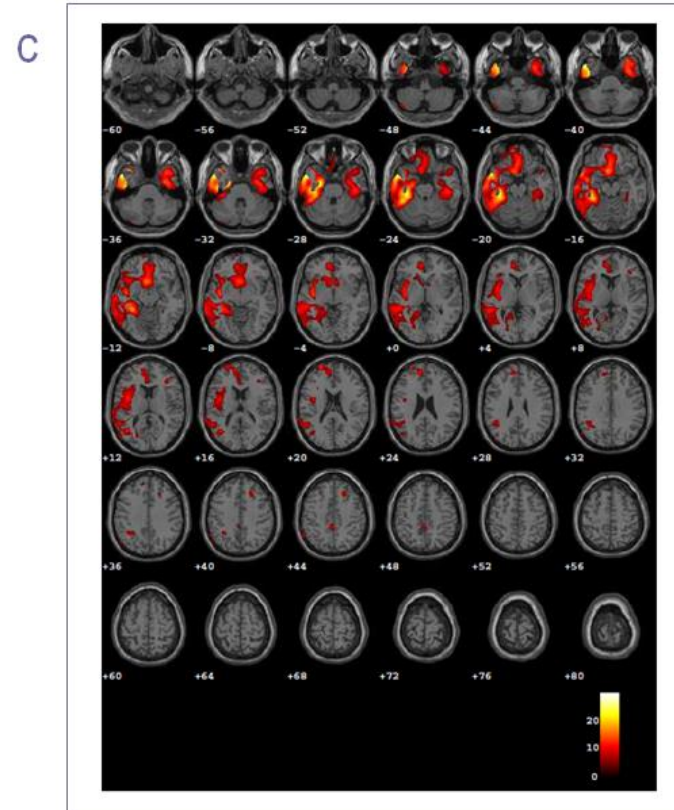


Figure 3. SPM-T map of hypometabolism (SPM5; <http://www.fil.ion.ucl.ac.uk/spm/software/spm5/>) of the single-patient [¹⁸F]FDG-PET scan compared to 112 normal scans and displayed at a voxel-wise corrected threshold ($p=0.05$, FWE) with a minimum cluster size of 100 voxels



Non fluent/agrammatic variant

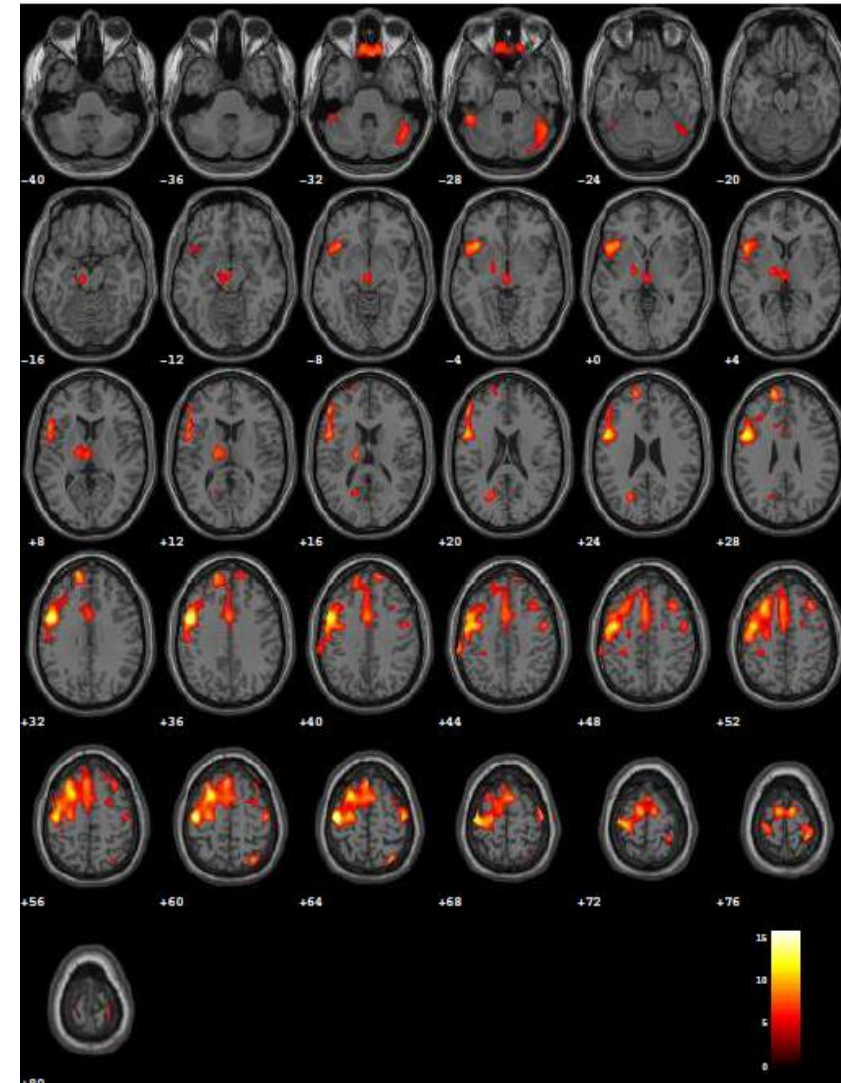
- **Nonfluent production with articulation impairment and agrammatism**
- Naming moderately impaired
- Preserved single word comprehension
- Defective comprehension of syntactically complex sentences

Case M.G. ♀ 62 years old, 17 years education

SPM-T map of hypometabolism of the single patient
[¹⁸F]FDG-PET scan compared to 112 HC (FWE)

☐ **Neuropsychological Evaluation** Language assessment

AREA INDAGATA	TEST	P. GREZZO	P. CORRETTO	P. EQUIVALENTE
LINGUAGGIO: denominazione orale nomi comprensione nomi (<i>word picture matching test</i>).....	CAGI:	48/48	48	4
		48/48	48	4
comprensione di ordini complessi.....	Token Test.....	33/36	30.50	2
Comprensione grammaticale uditiva.....	BADA:	58/60	Cut off: 58	Al limite
Comprensione grammaticale visiva.....		42/45	Cut off: 43	Deficitario
Accesso al lessico.....	Fluenza semantica.....	24	22	0
	Fluenza fonemica.....	10	5	0
Memoria semantica.....	Test Palma Piramide	48/52	45.77	Nella norma
Ripetizione	AAT:			
	Suoni	28/30		
	Parole	30/30		
	Parole straniere	30/30		
	Parole composte e sintagmi	29/30		
	Frasi	30/30		
	TOTALE	147/150	-	Nessun deficit
Letture.....	AAT:	30/30	-	Nessun deficit
Scrittura sotto dettato.....		30/30	-	Nessun deficit



Logopenic/phonological variant (original definition)

- Dysfluent speech, with anommic pauses, hesitations and phonological errors, but normal articulation and grammar
- Preserved single word comprehension
- Defective repetition and auditory verbal short-term memory
- Defective sentence comprehension

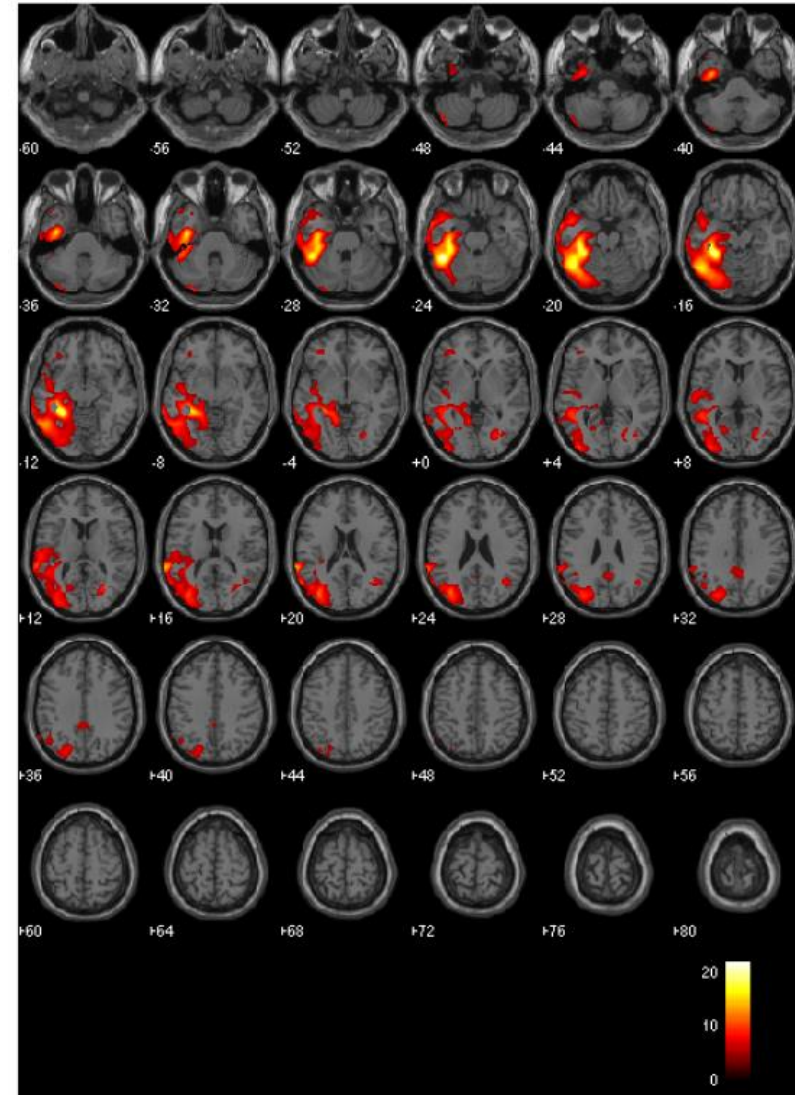
Case E.M. ♀ 77 years old, 10 years schooling, suspected PPA

Instrumental Evaluations

CSF A β 42 and Tau measures

LCR-BETA AMILOIDE (I-42)	269	ng/L	> 500	←
LCR-PROTEINA TAU	322	ng/L	0.0 - 500.0	
LCR-PROTEINA TAU FOSFORILATA	74	ng/L	0.00 - 61.00	←

SPM-T map of hypometabolism of the single patient
[¹⁸F]FDG-PET scan compared to 112 HC (FWE)



	NF/Av	Sv	L/Phv
Motor speech	Impaired (apraxia of speech)	normal	pauses, hesitations, phonological errors
Grammar	impaired	normal	preserved
Word-finding	mildly impaired	impaired, semantic errors	Impaired, anomias, phonemic paraphasias
Word comprehension	preserved	impaired early	preserved
Sentence repetition	motor impairment	preserved	impaired
Sentence comprehension	Impaired (grammatically complex sentences)	preserved	Impaired (long sentences)

Pathology (Spinelli et al., 2017)

- Nf/Av
 - FTLD Tau 88%
- Sv
 - TDP-C 83%
- L/Phv
 - AD 100%

Management

- Advice and support
- Symptomatic treatment: depression, behavioural disorders
- Speech and language therapy
- Neuromodulation

References

- Ash, S., Evans, E., O'Shea, J., Powers, J., Boller, A., Weinberg, D., . . . Grossman, M. (2013). Differentiating primary progressive aphasias in a brief sample of connected speech. *Neurology*, 81(4), 329-336
- Battista, P., Catricalà, E., Piccininni, M., Copetti, M., Esposito, V., Polito, C., ... & Picillo, M. (2018). Screening for Aphasia in NeuroDegeneration for the Diagnosis of Patients with Primary Progressive Aphasia: Clinical Validity and Psychometric Properties. *Dementia and Geriatric Cognitive Disorders*, 46(3-4), 243-252.
- Boschi, V., Catricalà, E., Consonni, M., Chesi, C., Moro, A., & Cappa, S. F. (2017). Connected speech in neurodegenerative language disorders: a review, 8, 269.
- Caffarra, P., Gardini, S., Cappa, S., Dieci, F., Concari, L., Barocco, F., . . . Prati, G. D. (2013). Degenerative jargon aphasia: unusual progression of logopenic/phonological progressive aphasia? *Behav Neurol*, 26(1-2), 89-93.
- Cappa, S.F., Cerami, C. (2016). Primary Progressive Aphasia. In Dickerson, B.C. (ed.) *Hodges' Frontotemporal Dementia*, Cambridge University Press
- Catani, M., Mesulam, M. M., Jakobsen, E., Malik, F., Martersteck, A., Wieneke, C., . . . Rogalski, E. (2013). A novel frontal pathway underlies verbal fluency in primary progressive aphasia. *Brain*, 136(Pt 8), 2619-2628.
- Catricalà, E., Gobbi, E., Battista, P., Miozzo, A., Polito, C., Boschi, V., ... & Cappa, S. F. (2017). SAND: a Screening for Aphasia in NeuroDegeneration. Development and normative data. *Neurological Sciences*, 38(8), 1469-1483.
- Cotelli, M., Borroni, B., Manenti, R., Alberici, A., Calabria, M., Agosti, C., . . . Cappa, S. F. (2006). Action and object naming in frontotemporal dementia, progressive supranuclear palsy, and corticobasal degeneration. *Neuropsychology*, 20(5), 558-565.
- Gorno-Tempini, M. L., Brambati, S. M., Ginex, V., Ogar, J., Dronkers, N. F., Marcone, A., . . . Miller, B. L. (2008). The logopenic/phonological variant of primary progressive aphasia. *Neurology*, 71(16), 1227-1234.
- Gorno-Tempini, M. L., Hillis, A. E., Weintraub, S., Kertesz, A., Mendez, M., Cappa, S. F., . . . Grossman, M. (2011). Classification of primary progressive aphasia and its variants. *Neurology*, 76(11), 1006-1014.
- Iaccarino, L., Crespi, C., Della Rosa, P. A., Catricala, E., Guidi, L., Marcone, A., . . . Perani, D. (2015). The semantic variant of primary progressive aphasia: clinical and neuroimaging evidence in single subjects. *PLoS One*, 10(3), e0120197.
- Mesulam, M. (2013). Primary progressive aphasia: A dementia of the language network. *Dement Neuropsychol*, 7(1), 2-9.
- Mesulam, M., Wicklund, A., Johnson, N., Rogalski, E., Léger, G. C., Rademaker, A., . . . Bigio, E. H. (2008). Alzheimer and frontotemporal pathology in subsets of primary progressive aphasia. *Ann Neurol*, 63(709-19).
- Mesulam, M. M., Rogalski, E. J., Wieneke, C., Hurley, R. S., Geula, C., Bigio, E. H., . . . Weintraub, S. (2014). Primary progressive aphasia and the evolving neurology of the language network. *Nat Rev Neurol*, 10(10), 554-569.
- Mesulam, M. M., Thompson, C. K., Weintraub, S., & Rogalski, E. J. (2015). The Wernicke conundrum and the anatomy of language comprehension in primary progressive aphasia. *Brain*, 138(Pt 8), 2423-2437.
- Montembeault, M., Brambati, S. M., Gorno-Tempini, M. L., & Migliaccio, R. (2018). Clinical, anatomical, and pathological features in the three variants of primary progressive aphasia: a review. *Frontiers in neurology*, 9.
- Rohrer, J. D., Ridgway, G. R., Crutch, S. J., Hailstone, J., Goll, J. C., Clarkson, M. J., . . . Warren, J. D. (2010). Progressive logopenic/phonological aphasia: erosion of the language network. *Neuroimage*, 49(1), 984-993.
- Spinelli, E. G., Mandelli, M. L., Miller, Z. A., Santos-Santos, M. A., Wilson, S. M., Agosta, F., ... & Henry, M. L. (2017). Typical and atypical pathology in primary progressive aphasia variants. *Annals of neurology*, 81(3), 430-443.
- Teichmann, M., Kas, A., Boutet, C., Ferrieux, S., Nagues, M., Samri, D., . . . Migliaccio, R. (2013). Deciphering logopenic primary progressive aphasia: a clinical, imaging and biomarker investigation. *Brain*, 136(Pt 11), 3474-3488.
- Wilson, S. M., Henry, M. L., Besbris, M., Ogar, J. M., Dronkers, N. F., Jarrold, W., . . . Gorno-Tempini, M. L. (2010). Connected speech production in three variants of primary progressive aphasia. *Brain*, 133(Pt 7), 2069-2088.